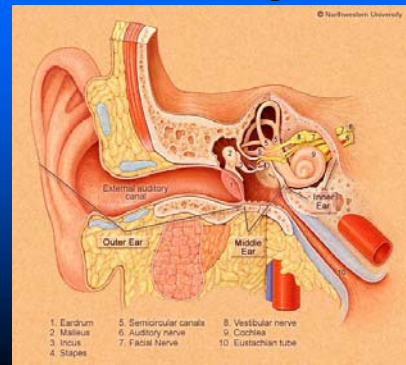


## Otologic Dizziness (Dizziness from Ear)

Timothy C. Hain, MD

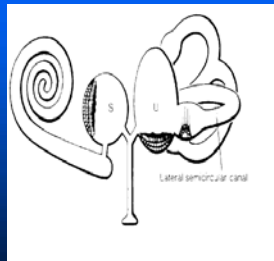Northwestern University, Chicago  
t-hain@northwestern.edu

## Structures of importance



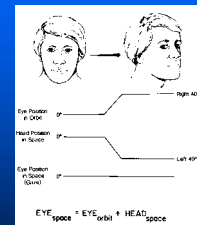
## The ear is an inertial navigation device

- Semicircular Canals are rate sensors.
- Otoliths (utricle and saccule) are linear accelerometers
- Bilateral symmetry means redundant design.



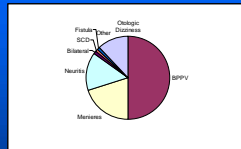
## Vestibular Reflexes

- VOR: Vestibulo-ocular reflex
- VSR: Vestibulospinal reflex



## Otologic (Ear) Dizziness

- BPPV (benign paroxysmal positional vertigo) -- about 50% of otologic, 20% all
- Meniere's disease -- about 20%
- Vestibular neuritis and related conditions (15%)
- Bilateral vestibular loss (about 1%)
- SCD and Fistula (rare but worth knowing)



## Positional Vertigo The most common syndrome

- Benign Paroxysmal Positional Vertigo (BPPV)
  - Orthostatic hypotension
  - Central positional nystagmus
  - Low CSF pressure syndrome

## Benign Paroxysmal Positional Vertigo (BPPV)

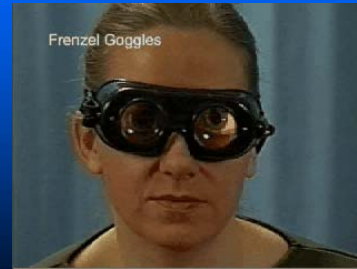61 Y/O man slipped on wet floor.

LOC for 20 minutes.

In ER, unable to sit up because of dizziness

Hallpike Maneuver: Positive

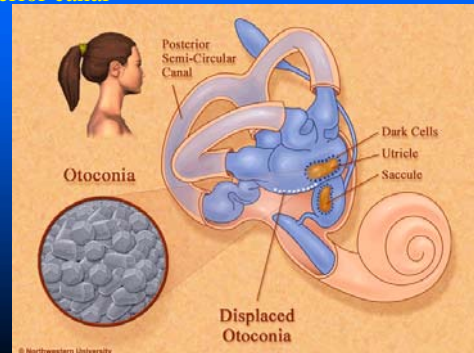
## Positional Vertigo Dix-Hallpike Maneuver



## Benign Paroxysmal Positional Vertigo (BPPV)

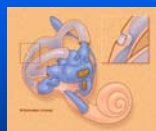- 20% of all vertigo
- Brief and strong
- Provoked by change of head position
- Definitively diagnosed by Hallpike test

BPPV Mechanism: Utricular debris migrates to posterior canal



## BPPV treatment

- Medication (e.g. antivert) – minor benefit
  - May avoid vomiting by pretreating
- PT – excellent results
- Surgery – canal plugging if rehab fails (need more rehab after plug)



## Unilateral Vestibular


- Vestibular Neuritis/Labyrinthitis (common)
- Meniere's disease (unusual, 1/2000 prevalence)
- Acoustic Neuroma (very rare)
- Vestibular paroxysmia

## Vestibular Neuritis: Case

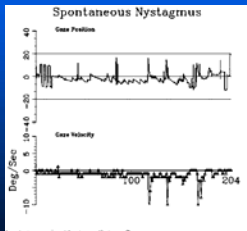
56 y/o woman began to become dizzy after lunch. Dizziness increased over hours, and consisted of a spinning “merri-go-round” sensation, combined with unsteadiness.

Vomiting ensued 2 hours later, and she was brought by family members to the ER.

## Vestibular Spontaneous Nystagmus seen with video Frenzel Goggles



## Vestibular Spontaneous Nystagmus recorded on ENG (Electronystagmography)



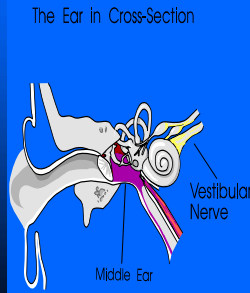
## Aside : how to examine for SN

- Frenzel Goggles (best)
- Ophthalmoscope (good –but backwards)
- Gaze-evoked nystagmus (pretty good)
- Sheet of white paper (neat)



## Vestibular Neuritis -- rx

- Viral infection of vestibular nerve or ganglion (Herpes).
- Disability typically lasts 2 weeks.
- Symptomatic Rx (meclizine, phenergan, benzodiazepine)
- Rehab if still symptomatic after 2 months.
- These patients can still get BPPV !

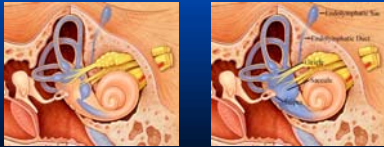

## Meniere’s Disease

- Prosper Meniere 1861
  - Fluctuating hearing
  - Episodic Vertigo
  - Fluctuating (roaring) Tinnitus
  - Aural Fullness
- About 1/2000 people in population
- Chronic condition – lasts lifetime

## Etiology of Meniere's

- Dilation and episodic rupture of inner ear membranes (Endolymphatic Hydrops)
- As endolymph volume and pressure increases, the utricular/saccular and Reissner's membranes rupture, releasing potassium-rich endolymph into the perilymph causing cochlear/vestibular paralysis



## Meniere's disease – symptoms

- Progressive hearing loss -- sometimes go deaf
- Episodic vertigo – out for several days
- Ataxia – gradually increases
- Visual sensitivity →

## Visual Sensitivity is common

- Sensory integration disorder – upweight vision, downweight everything else
- Grocery store, Omnimax, Target, etc
- Typical of disorders with intermittent vestibular problems



## Otolithic Crises of Tumarkin

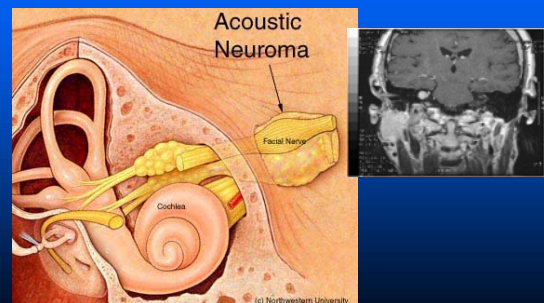
- Drop attacks
- Go from upright to on floor in fraction of second
- No LOC
- Very dangerous
- Destructive treatment



## Treatments of Menieres

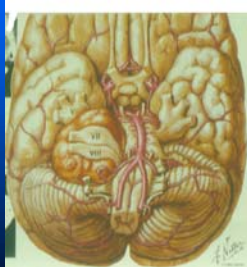
- Medical management –
  - Usually ineffective
- Surgery
  - Low dose gentamicin treatment works nicely
  - High dose gentamicin treatment
- Rehab doesn't generally help when fluctuating, but may be useful post surgery

## Acoustic Neuroma



## Acoustic Neuroma

- Cause of unilateral vestibular loss
- Rare cause of unilateral loss
- Generally also deaf on one side
- Slowly progressive – little or no vertigo



## Treatment of Acoustic Neuroma

- Watchful waiting (about 25%)
- Operative removal (about 50%) – losing ground
- Gamma Knife (about 25%) – gaining ground because effective and noninvasive

## Vestibular Paroxysmia (AKA microvascular compression)

- Irritation of vestibular nerve
- Quick spins
- Motion sensitivity
- May follow 8<sup>th</sup> nerve surgery
- Wastebasket syndrome in some cases ?

## Clinical Diagnosis of MVC

- Quick spins
- May have nystagmus on hyperventilation
- Response to anticonvulsant
- No rehab potential prior to surgery

## Bilateral Vestibular Loss

A stewardess developed a toe-nail infection. She underwent course of gentamicin and vancomycin. 12 days after starting therapy she developed imbalance. 21 days after starting, she was “staggering like a drunk person”. Meclizine was prescribed. Gentamicin was stopped on day 29. One year later, the patient had persistent imbalance, visual symptoms, and had not returned to work. Hearing is normal. She unsuccessfully sued her doctor for malpractice.

## SYMPTOMS OF BILATERAL VESTIBULAR LOSS

- OSCILLOPSIA



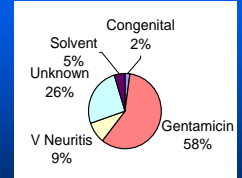
## SYMPTOMS OF BILATERAL VESTIBULAR LOSS

- ATAXIA



## Bilateral Vestibular Loss Causes:

- Ototoxicity !
- Bilateral forms of unilateral disorders (e.g. bilateral vestib neuritis)
- Congenital (e.g. Mondini malformation)
- idiopathic



N=43, NMH 1990-1998

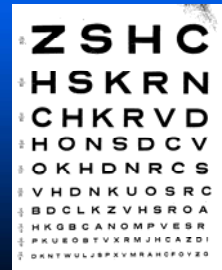## DIAGNOSIS IS EASY

- History of recent IV antibiotic medication
- Eyes closed tandem Romberg is positive
- Dynamic illegible 'E' test (DIE) failed

---->

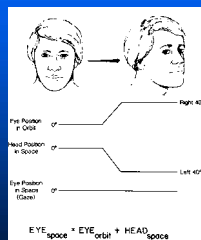
## Dynamic Illegible 'E' test (DIE test)

- Distance vision with head still
- Distance vision with head moving
- Normal: 0-2 lines change.
- Abnormal: 4-7 lines change



## Rapid Dolls failed

- VOR: Vestibulo-ocular reflex



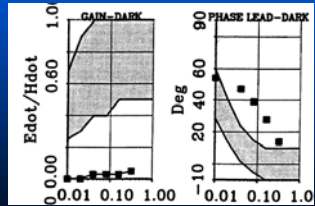
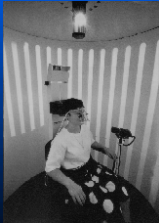## LABORATORY DIAGNOSIS

- ENG
- Rotatory chair
- VEMP



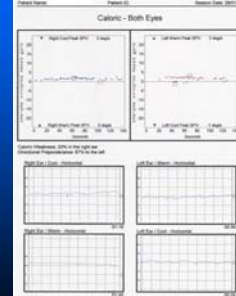
## DIAGNOSIS Continued

- Rotatory chair confirms diagnosis but requires cooperation



## DIAGNOSIS Continued

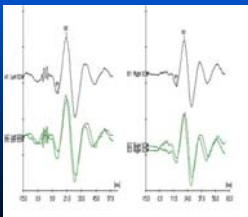
- ENG shows little or no response



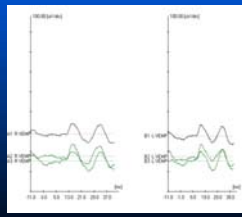
## DIAGNOSIS Continued

- VEMP is reduced in bilateral loss

NORMAL



BILATERAL LOSS

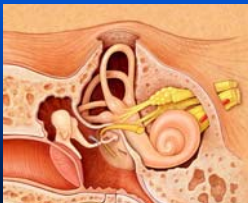


## Treatment Bilateral

- No medical management (other than avoiding more damage)
- Rehab is the only somewhat effective treatment
- Be prepared for a deposition

## Perilymph Fistula and SCD (superior canal dehiscence)

Fluctuating conditions  
No rehab until after surgery

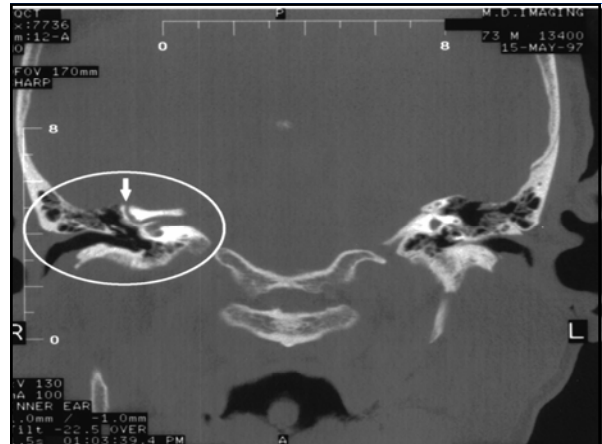
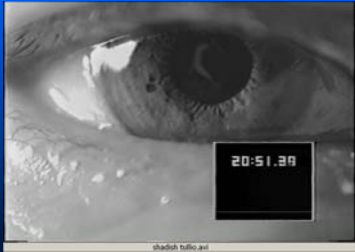
- Superior Canal Dehiscence

## Case: WS

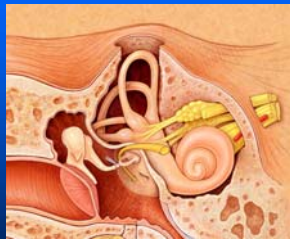
Retired plastic surgeon, with impaired hearing related to war injuries, found that when he went to church, when organ was playing, certain notes made him stagger. His otolaryngologist noted that during audiometry (with hearing aid in), certain tones reliably induced dizziness and a mixed vertical/torsional nystagmus. This "Tullio's phenomenon" could be easily reproduced experimentally. MRI scan was normal.

## Tullio in SCD



## Superior Canal Dehiscence

- Etiology:
  - Congenital bone defect (2% ?)
  - Trauma may exacerbate
- Treatment:
  - Surgical
    - » Plug
    - » Resurface

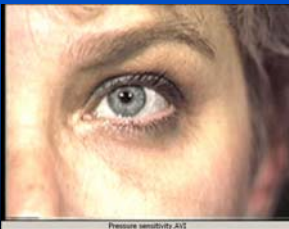

## Diagnosis of SCD

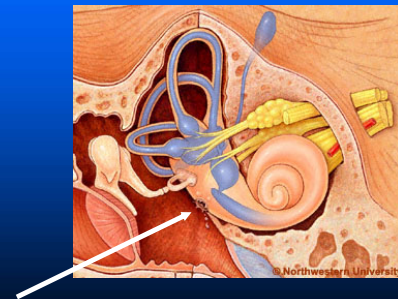
- Tullio's (clinical)
- Temporal Bone CT scan (high resolution)
- VEMP: Vestibular evoked myogenic potentials

## Case: KF

- After SCUBA diving, a young woman developed vertigo, aural fullness and tinnitus for 1 year.
- Symptoms were worsened by tragal pressure and straining. Surgery was performed.

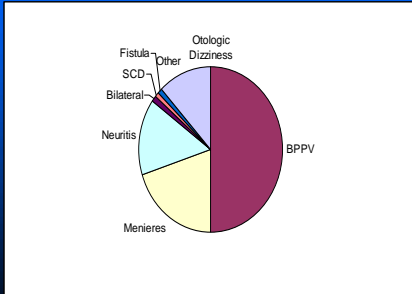


A large round window fistula was found and symptoms completely resolved after a second surgery.





## Summary of Otologic Vertigo



## More details

Hain, T.C. Approach to the patient with Dizziness and Vertigo. Practical Neurology (Ed. Biller), 2002. Lippincott-Raven

## More movies

[www.dizziness-and-balance.com](http://www.dizziness-and-balance.com)