

## Non-otologic Dizziness

Timothy C. Hain, MD  
Clinical Professor  
Neurology, Otolaryngology, Physical  
Therapy  
Northwestern University, Chicago  
t-hain@northwestern.edu

## Dizziness is an imprecise term

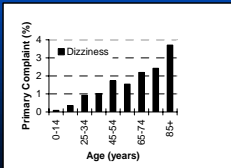
- Vertigo (sensation of motion)
- Lightheaded
- Ataxia
- Confusion



Because "Dizziness" is an imprecise term, a major role of the clinician is to sort patients

## Dizziness is VERY Common

- Dizziness is the chief complaint in 2.5% of all primary care visits.
- 30% lifetime prevalence of dizziness requiring medical attention
- Older people have more dizzy problems



Estimated percentage of ambulatory care patients in whom dizziness was a primary complaint (Sloane, et. al., 1989).

## Diagnostic Categories

<u>Category</u>	<u>Example</u>
■ Otological	■ Meniere's disease
■ Neurological	■ Migraine
■ Medical	■ Low BP
■ Psychological	■ Anxiety
■ Undiagnosed	■ Post-traumatic vertigo

## Question 1

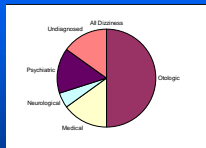
- Which category is associated with the most dizziness ?
  1. Inner ear disorders
  2. CNS problems (e.g. Stroke)
  3. Blood pressure
  4. Psychological problems
  5. Undiagnosed

## Answer 1

- It depends on your referral base
  1. Inner ear disorders (about 50% of ENT, 30% in general)
  2. CNS (about 25% of neurology, 5% everyone else)
  3. Blood pressure (30% of family practice, 5% everyone else)
  4. Psychological problems (15% to 50%)
  5. Undiagnosed (up to 50%)

## Diagnostic Categories – non-otologic dizziness

1. Neurological (i.e. posterior fossa)
2. Medical (i.e. low blood pressure)
3. Psychological (anxiety, malingering)
4. Undiagnosed



## Causes of neurological dizziness 15-30% subspecialty, 5% ER

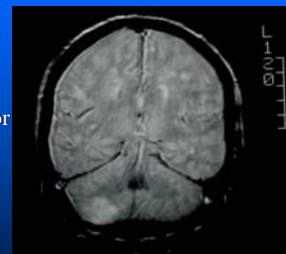- 35% Stroke and TIA
- 16% Migraine
- Various Ataxias
- Seizures
- Multiple Sclerosis
- Tumors
- Head Trauma
- CSF pressure abnormalities - -CSF leak, NPH

## Carotid disease does not cause dizziness

- Carotids supply anterior brain. No dizziness circuitry there. Carotid disease causes weakness/numbness/speech disturbance
- Carotid endarterectomy rarely helps dizziness

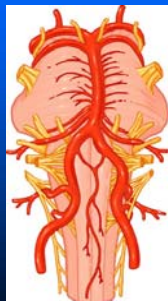## Posterior Fossa stroke

- 50 year old doctor developed vertigo and unsteadiness
- Continued to operate for a week before seeking medical attention but wife wouldn't let him drive.
- PICA stroke seen on MRI



## Common Strokes with Dizziness

- PICA (lateral medullary and cerebellum) – palatal weakness
- AICA (pons and cerebellum) – hearing loss
- SCA (cerebellar)



## Posterior Inferior Cerebellar Artery (PICA) Wallenberg's Syndrome Lateral Medullary Syndrome

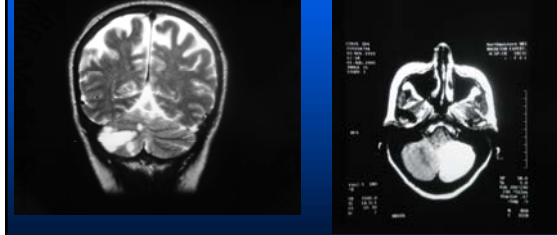
- Adolf Wallenberg

German internist, born November 10, 1862, Preuss.-Stargard. died 1949.



## Case (IC)

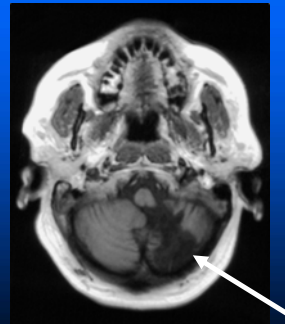
- Onset of dizziness 1 week ago
- Unable to walk
- Diabetes and new onset a-fib
- Exam:
  - Ataxic but intact VOR
  - No spontaneous nystagmus
  - Neuropathy



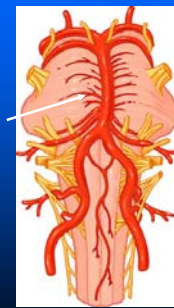## Basilar Artery syndrome (C.A.)

A 44 year old woman was involved in a rear end collision. She had a whiplash injury, and apparently the vertebral arteries in the neck were contused. Several days after the accident she became comatose, and studies suggested complete occlusion of the basilar artery.

Cerebellar infarct



Basilar artery



## Basilar artery case findings (1991 vs. 2001)

- |                                         |        |
|-----------------------------------------|--------|
| ■ Unsteady Gait                         | ■ Same |
| ■ Finger to nose ataxia                 | ■ Same |
| ■ Nystagmus (eyes moving involuntarily) | ■ Same |

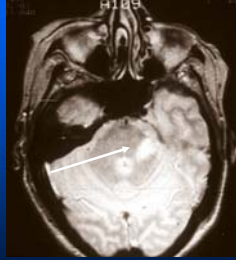
Basilar artery strokes are often fatal.

## Common features of cerebellar gait ataxia

- Severe impairment of balance (worse than sensory balance disorders)
- Wide based gait
- Often refractory to treatment and time

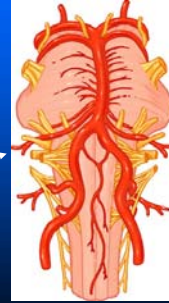## Anterior inferior cerebellar artery Case

- Woman with diabetes, obesity, hypertension suddenly becomes dizzy, and develops facial weakness in swimming pool.
- Brought into hospital and CT scan shows stroke in pons.



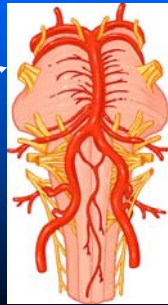## Anterior inferior cerebellar artery AICA syndrome

- AICA supplies pons, cerebellum, 8<sup>th</sup> nerve
- Facial weakness
- Vertigo/hearing loss
- Incoordination



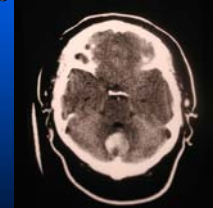
## Superior Cerebellar Artery SCA Syndrome

- SCA supplies superior cerebellum and midbrain
- Ataxia and diplopia



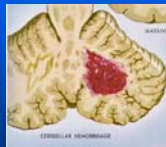## Hemorrhagic Cerebellar Stroke

- Signs/Symptoms
  - Ipsilateral or diffuse cerebellar signs
  - Occipital headache
  - Signs of increased ICP
    - » Projectile vomiting
    - » Confusion
- Causes
  - Hypertension, tumors, trauma



## Hemorrhagic cerebellar stroke

- Also can bleed into substance of cerebellum
- Differences from ischemic stroke
  - Much more dangerous
  - Can swell and compress brainstem
  - Surgery is common to decompress

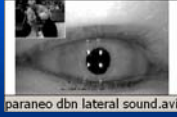

## Paraneoplastic syndromes -- case

- 35 year old woman admitted to hospital because very unsteady – poor coordination
- Many tests were done without a diagnosis. Nobody did a breast exam.
- 1 year later noticed a large breast lump
- Breast cancer removed – but patient left with severe cerebellar syndrome

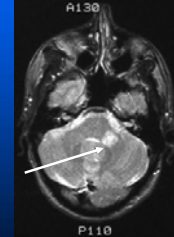
## Paraneoplastic syndromes

- Remote effect of cancer
- Associated with lung and breast cancer
- Vestibulo-cerebellar syndrome – dominated by
  - Ataxia
  - Nystagmus (particularly downbeating)
- May be related to autoantibodies



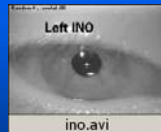## Multiple Sclerosis (MS)

- No single pattern
- Multiple lesions distributed in time and space



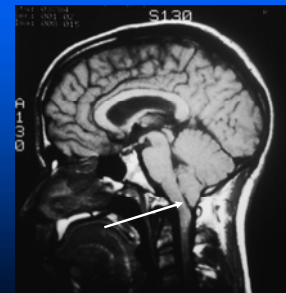
## Multiple Sclerosis (MS)

- INO is common in MS




## Chiari Malformation: Case

- Dock worker in Baltimore came in because gets dizzy when lifts heavy boxes
- Examination: unsteady, downbeating nystagmus.
- MRI showed cerebellar tonsils lower than normal.

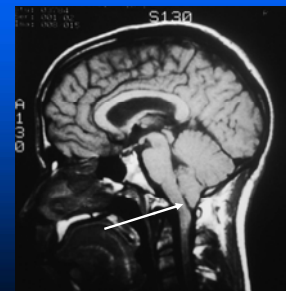


## Downbeating Nystagmus may be clue to underlying cerebellar degeneration or Chiari



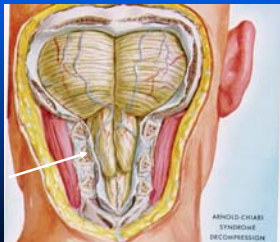
## Chiari Malformation

- Cerebellar tonsils herniate downward
- Adult onset
- Straining or coughing produces headache or fainting
- Unsteadiness
- Nystagmus



## Chiari Malformation Treatment: Suboccipital decompression

Arrow points to tonsils. This surgical exposure is larger than would be used in real operation



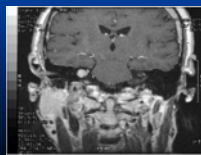
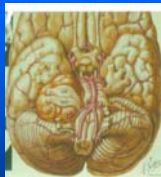## Non-otologic ataxias – all of neurology ?

- Cerebellar
- Basal Ganglia
- Hydrocephalus
- Sensory loss (B12)
- Periventricular WM lesions
- CSF leak
- Drugs (e.g. anticonvulsants)
- Degenerations (e.g. PSP, Palatal myoclonus)

## Brain Tumors Causing Dizziness

We worry a lot about these rare disorders

- Acoustic Neuroma (rare)
- Meningioma
- Cerebellar astrocytoma
- Cerebellar hemangioblastoma

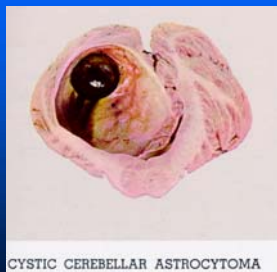


## Cerebellar Astrocytoma Case

- Young woman in residency training
- Developed a headache and went to ER. In ER a CT scan was done.
- A large tumor was found occupying most of right side of cerebellum.
- Tumor was removed – after operation patient developed incoordination R side. Over 6 months, has improved so much can return to training program.

## Cerebellar Astrocytoma

- Largely in children
- Slowly growing tumor
- Cerebellar hemisphere syndromes
- Resection often cures

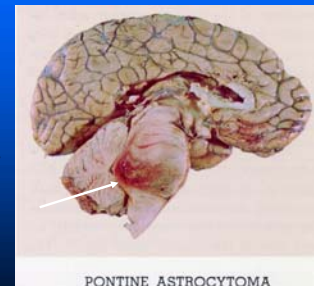


CYSTIC CEREBELLAR ASTROCYTOMA

Rubinstein L, Tumors of the Central Nervous System

## Pontine Astrocytoma

- Largely in children
- Slowly growing tumor
- Affects cerebellar connections
- No treatment – fatal disease

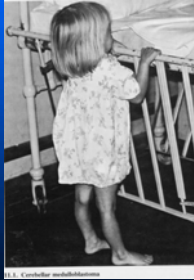


PONTINE ASTROCYTOMA

Rubinstein L, Tumors of the Central Nervous System



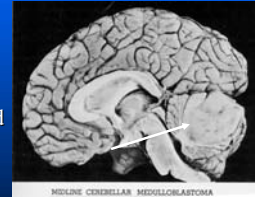
This child is holding onto the bed rail due to ataxia from a medulloblastoma



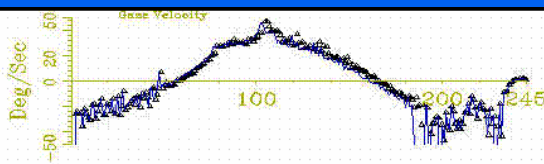
Severe ataxia  
Strong positional nystagmus

## Cerebellar Medulloblastoma

- Mainly affects children
- Begins in cerebellar nodulus -- vestibulocerebellum
- Hydrocephalus (projectile vomiting) and cerebellar signs.
- Treat with resection, chemotherapy and radiation.
- 5 year survival – 80%

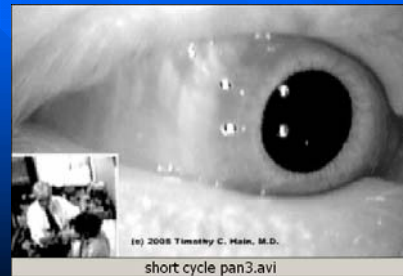

## Periodic Alternating Nystagmus (PAN)



Congenital and acquired forms. Acquired form usually from cerebellar nodulus lesion (such as medulloblastoma). Usual period is 200 sec.

## PAN – example (CN type)



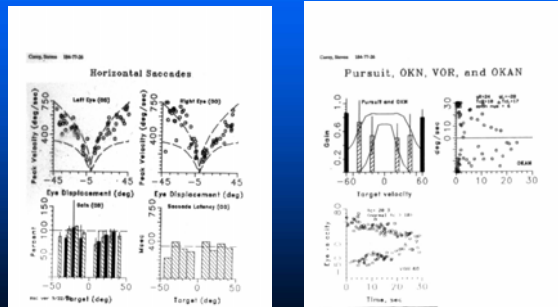
## Treatment of Central Dizziness

- Vestibular Suppressants
- ? Agents that promote compensation
  - Betahistine, Amantadine, Baclofen
- Vestibular rehabilitation
- Environmental adaptations

## Case

- 8 Year old became dizzy playing video games
- Mother noted the eyes jumped
- Transient confusion

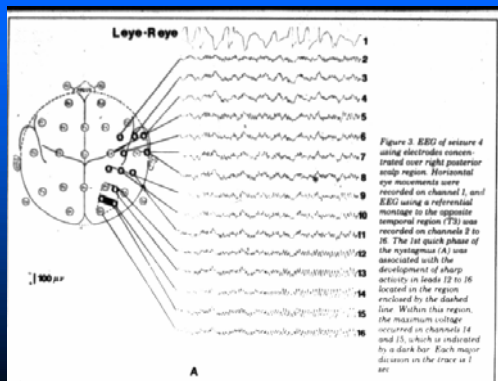
## Normal Oculomotor and Vestibular Tests



In the clinic he had a spell of dizziness with clear nystagmus



EEG shows seizure during nystagmus



## Seizures causing Dizziness

- Quick spins (1-2 seconds)
  - Also caused by vestibular nerve irritation
- Confusion and dizziness
- May be triggered by flashing lights
- Head injury is common
- Oxcarbamazine may stop them

## Migraine & Vertigo: Prevalence

- Migraine:
  - 10% of U.S. population has Migraine†
  - 20-30% of women childbearing age
- Vertigo: 35% of migraine population.\*
- Migraine + vertigo (MAV):
  - ~ 3.5% of U.S. pop.
  - ~ 10% of women of childbearing age

† Lipton and Stewart 1993; Stewart et al, 1994

\*Kayan/Hood, 1984; Selby/Lance, 1960; Kuritzky, et al, 1981

## Diagnosis of MAV Nystagmus

- No definitive pattern
- Often low amplitude downbeating or upbeating nystagmus
- ? Due to cerebellar disturbance



## Diagnosis of MAV

Clinical judgment

- Headaches and dizziness
- Lack of alternative explanation (normal otological exam, neurological exam, CT)
- High index of suspicion in women of childbearing age. Perimenstrual pattern.
- Family history in 50%
- Response to prophylactic medication or a triptan

## CSF pressure problems

### Orthostatic symptoms

- CSF leak
  - Post-LP dizziness/nausea/headache
  - Post-epidural dizziness/hearing loss/tinnitus
  - Idiopathic
- No nystagmus

## CSF-pressure problems

### Normal pressure hydrocephalus

- Ataxic/Apraxic gait
- No vertigo, hearing problems or cerebellar signs
- Respond to spinal tap followed by shunt

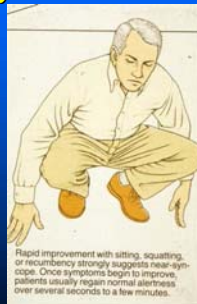
## Diagnostic Categories

- Neurological (i.e. posterior fossa)
- **Medical**
- Psychological (anxiety, malingering)
- Undiagnosed

## “Medical Dizziness”

### 30% of ER dizzy cases

- Cardiovascular (23-43%)
  - Orthostatic hypotension
  - Arrhythmia
- Infection (4-40%)
- Medication (7-12%)
- Hypoglycemia (4-5%)



Source: Madlon Kay (85), Herr et al (89)

## Psychogenic Vertigo

### Substantial – perhaps 20%

- Anxiety, hyperventilation, panic, Agoraphobia
- Somatization
- Malingering

## Anxiety

- Long-duration dizziness
- Situational
- Responds to benzodiazepines
- Some have vestibular disorders too

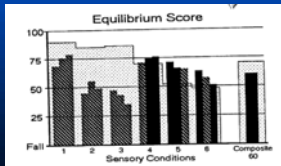


## Somatization

- Chronic dizziness
- Numerous bodily ailments
- One goes away to be replaced by another
- We don't have a treatment for SD.
- Do not tell these people there is "nothing wrong". Rather, try to minimize the health-care cost.

## We have several good tests for Malingering

- Moving Platform Posturography -- An algorithm for detecting inconsistency (Cevette score)

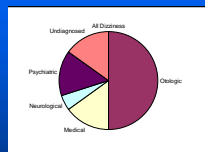


## Undiagnosed Dizziness

- About 15% of all dizzy patients
- Our tests are not 100% sensitive
- We are not perfect either

## Summary – non otologic dizziness

- Neurological (i.e. Migraine, posterior fossa)
- Medical (i.e. low blood pressure)
- Psychological (anxiety, malingering)
- Undiagnosed



## More details

Hain, T.C. Approach to the patient with Dizziness and Vertigo. Practical Neurology (Ed. Biller), 2002. Lippincott-Raven

## More movies

[www.dizziness-and-balance.com](http://www.dizziness-and-balance.com)